



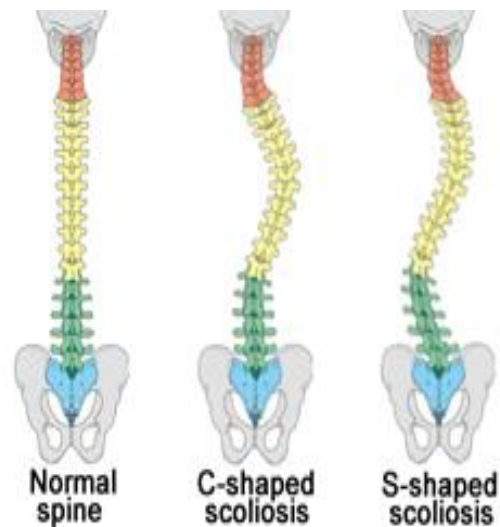
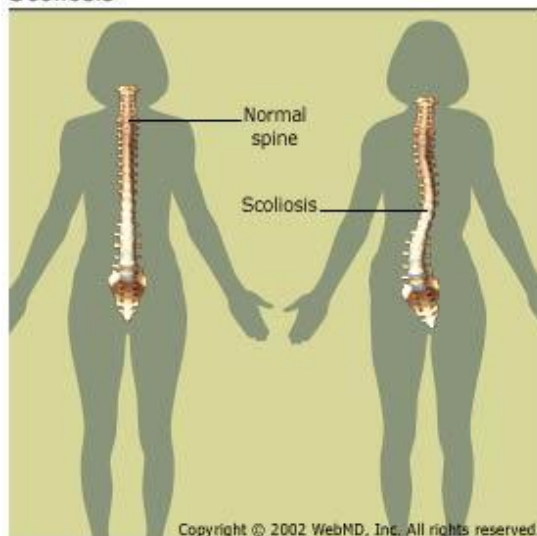
Osteopathy and Adolescent Idiopathic Scoliosis

Bridget Fearon
8/21/2015

Osteopathy and Adolescent Idiopathic Scoliosis

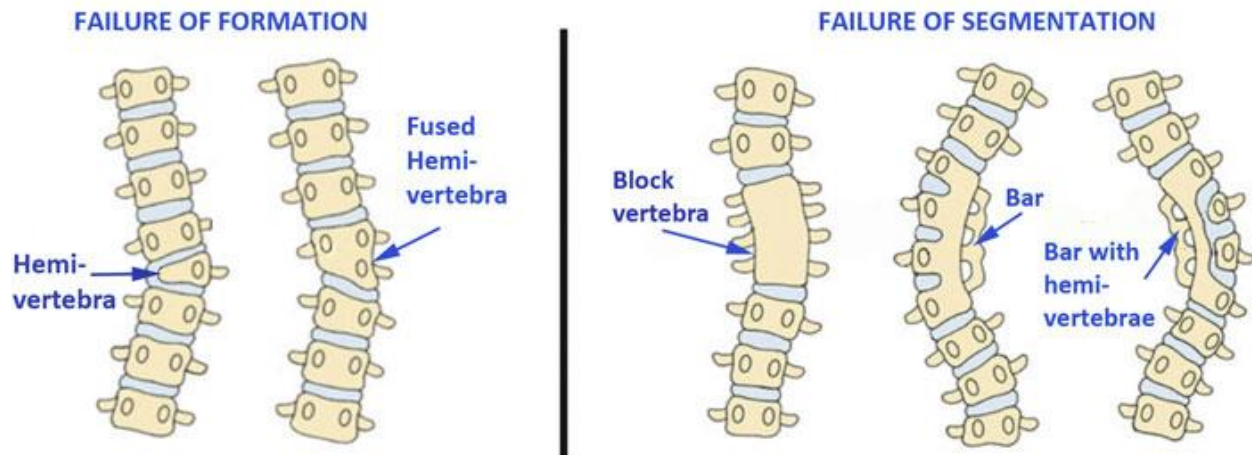
Scoliosis is an abnormal lateral curvature of the spine. It affects 2-3% of the population worldwide. (Information and Support) The word comes from the Ancient Greek word, scoliosis, meaning “bending” (dictionary.com) While it occurs equally among both genders, females are 8 times more likely to progress to a curve that requires treatment. (NRS) It is normal to have curves in the spine. A normal spine should be straight when viewed from the front (anteriorly) or back (posteriorly) (Palmer) and has 3 curvatures that allow for proper movement and shock absorption. These curves are anterior to posterior forming moderate lordosis in the cervical and lumbar spine and a moderate kyphosis in the thoracic spine. When viewing the spine from the side (laterally), the spine normally appears to resemble a soft “S” shape. (Eidelson) The spine can display different forms of abnormality, such as excessive lordosis (usually in the lumbar spine giving the appearance of a swayback) and excessive kyphosis (leading to the appearance of a humpback or hunchback). However, in a spine with scoliosis, in addition to the normal anterior to posterior lordosis and kyphosis, the spine also displays abnormal curvatures that are to the left or right side (lateral). Depending on the amount and type of curvature, instead of looking straight, the spine takes on a “C” or “S” shape. If this this curvature is marked enough, the clinician will also notice an increased kyphosis or roundness in the upper back and some increased lordosis or swayback appearance in the lower back. (Eidelson)

Scoliosis



www.duranchiro.co.za

There are many types of scoliosis each with a different cause. They are typically classified as congenital, neuromuscular, or idiopathic. Congenital scoliosis, although rarely hereditary, is caused by vertebral abnormalities present at birth. It is caused by a failure of the vertebrae to individually form or separate from each other. In other words, it is a birth defect in the spine (NASS). It is fairly uncommon, with approximately one person in every 10 000 affected. (What is congenital scoliosis?) The only treatment for congenital scoliosis is surgery as the bones themselves are deformed. Exterior bracing, exercise and manual therapy will have limited affects. (What is congenital scoliosis?)



<http://rltwnf.tistory.com/entry/hemivertebra>

Secondary scoliosis is present as a result of another condition. This type is sub divided into two categories: neuromuscular and degenerative. Neuromuscular scoliosis is commonly seen when there are problems with the myoneural pathways, such as in cases of cerebral palsy, spinal bifida, or spinal muscular atrophy. It is also seen in people with conditions that may result in paralysis. Unlike idiopathic scoliosis, the progression of neuromuscular scoliosis tends to progress more frequently and continues into adulthood. (Dobbs) While bracing may stabilize the curve, most cases require surgery after the adolescent growth spurt. (Dobbs) Degenerative scoliosis patients often seek help in their late fifties and sixties. Degenerative scoliosis may also be divided into two types. First are people who already have scoliosis and the wear and tear of aging or osteoarthritis causes the spine to collapse and progress the existing scoliosis further. (scoliosis.org) The other type may be caused from a traumatic incident, such as an injury or illness, that causes bone collapse asymmetrically, previous major surgery and osteoporosis (as it causes bone density to decrease leading to bone collapse). (WebMD) For most patients with degenerative scoliosis exercise, especially aerobic exercise such as swimming and cycling, along with non-steroidal anti-inflammatory drugs, bracing and occasionally surgery is used as treatment. Manual therapy can also help release muscle tension, release endorphins and ease discomfort. Congenital, secondary and degenerative scoliosis cases are different from idiopathic

Bridget Fearon
August 21, 2015
Diploma in Osteopathic Manual Practice
National Academy of Osteopathy

scoliosis and require the primary cause to be treated as well as different scoliosis treatments than the idiopathic scoliosis patient.

In idiopathic scoliosis, the cause is unknown. (NASS) It is sub classified as infantile (occurs before age 3 and is seen more frequently in boys), juvenile (occurs between ages three and ten and is found more frequently in girls), adolescent (It is also called adolescent idiopathic scoliosis or AIS, it occurs between age eleven and skeletal maturity, often at the onset of puberty and becomes apparent during an adolescent growth spurt. It is more severe among girls) or adult (after skeletal maturity) depending when the onset occurred. (Shaffrey)

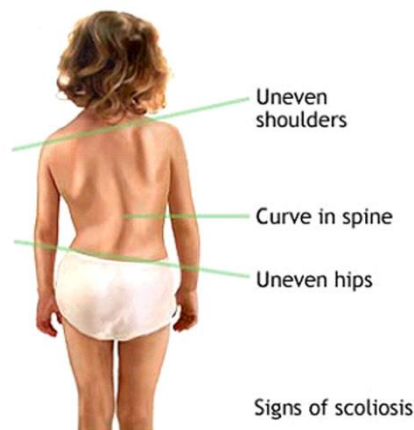
Idiopathic scoliosis is the most common type. In fact, 85% of the cases are considered idiopathic, with adolescent idiopathic scoliosis being the most prevalent. (Information and Support) It is diagnosed by ruling out other diseases or causes. (NASS) For example, through x-ray one can rule out congenital scoliosis as there won't be any abnormal bone present in the x-ray. (What is congenital scoliosis?) They will also rule out conditions that would indicate secondary scoliosis. As stated, the cause is unknown. One study stated that children born to mothers over the age of 27 are more likely to develop scoliosis but that study has never been duplicated. Many other theories are being explored but there hasn't been anything conclusive. A genetic root has been strongly suggested in research as there seems to be a greater incidence of heredity of idiopathic scoliosis compared to the other types. (Mehlman)

Scoliosis has been around for approximately 4000 years. Unfortunately, it is still poorly understood. Treatment has changed from Lord Krishna in Ancient Hindu literature straightening a back by "pressing down on her feet and pulling up on her chin." (Mehlman) Hippocrates, around 400 BCE, stated that scoliosis was due to posture and musculature. His beliefs lasted for thousands of years and is still followed by some. (Mehlman) In the 1500's, Ambroise Pare was the first physician to treat scoliosis with a brace and realize that treating an adult with a brace wasn't very effective. (Mehlman) Treatments in the 1700 consisted of rest, suspension, postural approaches and padded corsets. During the 1800's, in France, Jacques Mathieu Delpech used exercise to strengthen muscles of the trunk as he believed that scoliosis was due to weakness in the trunk muscles. He also used stretching and traction. (Mehlman) Finally, starting in the 1900's surgery has been used with increasing success to correct the curvature and reduce progressions. (Mehlman)

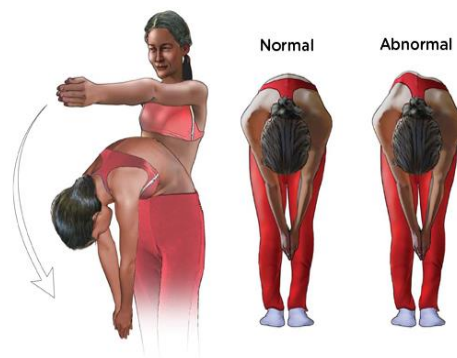
Early diagnosis is important. If scoliosis is left untreated it may progress, leaving the spine stiff and sometimes rigid, making treatment difficult and increasing the risks of complications. (Eidelson) Because adolescent idiopathic scoliosis is often painless with no decreased strength or

range of motion, it is usually identified when a family member, school screening or family physician notices shoulder asymmetry (one shoulder height than the other), waist line asymmetry or tilt, trunk shift (due to a rib hump) and leg length inequality. (Mehlman) Another common place for scoliosis to be noticed is by manual practitioners, such as manual osteopaths, massage therapists and chiropractors. Once the asymmetry is noticed, the practitioner takes a medical history of the problem. This history taking should include checking that there isn't another cause and if there is a family history of the disease. Neurological examinations may also be done to assess if there are underlying neurological problems that may be causing the scoliosis. The patient's age and onset of puberty (menarche in girls) is documented as it will determine how many years of growth are likely left, which will help predict progression and treatment. In addition to the visual asymmetries, the manual practitioner or physician can do a physical exam. This exam can include the Adam's Forward bending test. When viewed posteriorly, scoliosis is suspected if a thoracic or lumbar prominence is apparent. This hump can then be measured, in degrees, with a Scoliometer. (There is a Scoliometer app called Scolioscreen that can be purchased for an iPhone that can help patients monitor this at home.) The Scoliometer is placed over the rib hump while the patient is bent at the waist. Leg length can be measured to determine if there is a discrepancy. Sometimes this give the appearance of scoliosis even if it is not present. This is sometimes referred to as mechanical scoliosis. I plumb line held posteriorly at the 7th cervical vertebra can be used to see if portions of the spine fall to either side. Finally, palpation and range of motion is done to note asymmetry and movement. (Eidelson)

Asymmetry seen in scoliosis



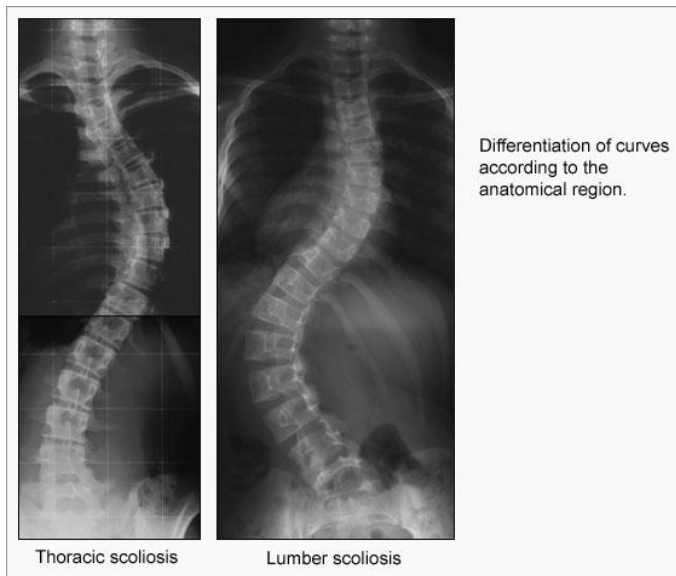
Adam's Forward Bending Test



<http://sfcustomchiro.com/scoliosis/>

<http://www.choa.org/Childrens-Hospital-Services/Orthopaddics/Programs-Services/Scoliosis-Screening/What-is-Scoliosis>

If there are signs of scoliosis, the physician will then order x-rays with the patient standing in the anterior/posterior plan and the lateral plane. Measurements are made to determine the type of curve and its severity. In the x-ray below, two types of spinal curves can be seen from a posterior view, as well as the asymmetry of the shoulders and hip and the rib hump.



<http://dxline.info/diseases/scoliosis-curvature-of-the-spine>

There are several factors that are taken into consideration when coming up with a treatment plan for a patient with scoliosis. Generally, the decision of what to do is based on the curve in degrees and the likelihood of progression. Using these factors, a Risser sign number between zero and five is given. The smaller the Risser sign number, the more growth is remaining. (NASS) Spinal maturity is considered. Is the patient still growing? The degree of the curvature and whether or not it is affecting the patient's lifestyle. The location of the curve along the spine as according to the Scoliosis Research Society, thoracic curves are more likely to progress than thoracolumbar. (iScoliosis) There is generally 3 accepted forms of treatment: observation, bracing, and surgery. Manual treatments and exercises are also available choices of treatment.

Curve in Degrees	Treatment
0-20°	Observe for progression
20-25°	Brace if progression documented, and substantial growth remaining
25-30°	Brace if progressive and growth remains
30-40°	Brace if growth remains
40-45°	Brace if growth remains versus surgery
>50°	Surgery

(NASS)

Observation is used when curves are small and have low risk of progression. Generally smaller curves are less likely to progress than larger curves so patients with curves less than 20° are usually observed. Follow up x-rays are used to confirm that the curve is not progressing. (SRS)

If the curve is between 20° and 45°, then the practitioner will decide if bracing is required or if the patient should just be observed for further change. (NASS) An example of when observation would be done is if the patient has stopped growing as this type of scoliosis typically do not progress after this point. This decision is based on the patient's age and if female whether or not menses has started. Female growth generally slows after the start of menstruation and ends within 18 - 24 months after. (SRS) If it is determined that the patient is likely to continue growing, a brace will likely be advised to slow the progression of the curve. The brace is not intended to reduce the size of the curve. (iScoliosis)

In the past, plaster casting was routinely used to treat scoliosis. Casting is no longer used in countries where braces are available except in some cases of infantile scoliosis. Currently there are several different kinds of braces. They are typically made of plastic that is custom formed to the patient's body, with padding and straps to provide resistance to the spine curves present. (iScoliosis). While is some controversy about the effectiveness of bracing, the Scoliosis Research Society have several studies that claim bracing can stop curve progression in 74 % - 93% of female patients. Braces may be prescribed to be worn anywhere between 8-23 hours per day. Most activities can be performed while wearing the brace. (iScoliosis) One issue with bracing is compliance. Studies have shown that compliance to brace-wear regimes are poor, often caused by psychological stress and lower levels of self-esteem associated with having scoliosis and with wearing a brace. (Mehlman)

As osteopathy is a holistic therapeutic approach, many osteopaths believe that during observation and bracing improvements can be made by use of osteopathic measures. In osteopathy, scoliosis patients receive individualised treatment, depending on their age, sex, general state of health, manifestation of curvature and lesion patterns. The approach is very heterogeneous, not only because of the holistic nature of osteopathy but also, possibly, because of the complex clinical picture. (Loibner-Gruendler)

Surgery is usually recommended when the patient have a curve over 40° and is still growing or if the spine curve exceeds 50° . Smaller curves are not likely to progress after skeletal maturity, however, curves of 50° or more tend to continue to progress at a rate of 1° a year. The type of surgery chosen depends on the type of curve, the curve flexibility and the location of the curve. Fusion is the most common choice, where the vertebrae are fused together with screws, rods, hooks, and wire to help hold the correction in place. (NASS) The goal of surgery is to stabilize spinal segments, correct deformity within safe parameters and enhance spinal fusion. Generally, the patient will stay in the hospital for 5-7 days after the surgery. (SRS) The patient may be mobile after 24 hours but on pain medication for 2-4 weeks (Rodts) and can usually return to regular daily activity and return school in 3-4 weeks (SRS). The incision should heal in 1-2 weeks and the fusion should be completely healed in 6-9 months. Results are not instant but should be seen at around the 6 month mark. Heavy lifting, bending, twisting and contact sports should be avoided until the fusion is completely healed. (Rodts)

In addition to observation and bracing, many other non-surgical treatments exist. If there is a great deal of pain injection treatments may be used. Acupuncture and herbal supplements have also been used for pain reduction. Other non-surgical treatments include: activity modification, chiropractic, directional exercises using mechanical diagnosis and therapy, electrothermal modalities (i.e., TENS, Ultrasound, superficial heat, lasers, etc.), ergonomic changes, physical therapy (i.e., aquatic exercise, core training, stretching, strengthening etc.), postural training, traction, and watchful waiting & education. (NASS)

Manual therapy, such as manual osteopath techniques can be used as a treatment for scoliosis by using hands on techniques to affect soft tissues, bones and joints of patients. Techniques most commonly used in a manual osteopath session are mobilization, soft tissue therapy, traction and muscle energy techniques. (NASS) Manual therapists often also employ many of the non-surgical treatments listed above.

Therefore, osteopathy offers a wide range of treatments for scoliosis through techniques which regulate strain in various tissue structures and planes. Structural, visceral and cranio-sacral

techniques are applied according to diagnostic findings on individual cases of scoliosis. It is the overall aim to reduce the rigidity of scoliosis, to balance out dysbalances caused by strain in myofascial, ligament and membrane tissue, to harmonise cranio-sacral dysfunctions, to improve metabolism in general, and thus to reduce the curvature degree of the spine, to stop or slow down the progression of scoliosis, and to prevent restrictions in the cardio-pulmonary tract. According to studies by Mandl-Weber (2000), and Phillip et al. (2004) osteopathic treatment leads to better therapy results with scoliosis than in control groups treated with traditional methods. (Luftinger)

However, while osteopathic treatment is often used as part of a treatment plan for AIS, there are not a lot of scientific studies to support the use of manual therapy in the treatment of scoliosis. In fact, according to the website <http://dxline.info/diseases/scoliosis-curvature-of-the-spine>, “There is no reliable evidence that other techniques such as osteopathy, chiropractic, physiotherapy, reflexology, acupuncture, neurostimulation, and so on, can make any difference to a scoliosis. However, these complementary techniques can sometimes be useful to improve backache or pain.” The webmed website backs up this claim in saying that many studies have shown that electrical stimulation, exercise programs, and manipulation are of no benefit in preventing the progression of scoliosis. However, people with scoliosis should stay active and fit.

Less invasive and non-surgical treatments are often sought by patients. In a review of 145 texts, Romano and Negrini only found three papers (case reports) that were relevant to their study and none of these texts could be used as they utilized manual therapy along with other therapeutic approaches. Therefore Romano and Negrini were unable to draw any conclusions on the effectiveness of manual therapy on adolescent idiopathic scoliosis.

Luftinger, in her thesis, refers to Nusselein’s opinion that a synchondrose sphenobasilaris (SSB) torsion as one of the possible causes of idiopathic scoliosis. However, because the diagnosis of an SSB-torsion is through palpation by osteopaths, it is considered a “vague” model and therefore, not proven by any scientific test. In her research, she states Liem’s belief that this torsion is traumatic and may occur at birth, maybe through use of forceps, or from a fall on the sacrum as a youth causing a torsion through the dura mater. Other studies that Luftinger refer to show that there is a possible connection with a malfunction in the cranial-sacral mechanism. Again the examiner’s results were found through palpation and were thus not considered a reliable test. Luftinger also notes that Liem describes some intra-ossal dysfunction due to forces on the sphenoid in the womb that may lead to scoliosis. In her research, it is suggested that according to assumptions by Liem, these asymmetries are present in infancy but are not diagnosed by a doctor until a later time but suggests that these tension dysbalances can be palpated by osteopaths before it is diagnosed medically. According to Luftinger, Liem also believes that disruptions in the muscular-fascial-skeletal system and visceral disruptions can

cause SSB-torsion and may explain the development of idiopathic scoliosis. However, there is not scientific proof. According to Luftinger, a pediatric osteopathic manual postulates that birth trauma are possible triggers for idiopathic scoliosis from SSB dysfunctions, compression of the SSB, dysfunctions of the sacrum and ilia and inward rotation of the hip joints and other muscular-fascial dysfunctions. Given these beliefs, it would seem possible that osteopathic mobilizations and cranial-sacral work could have an impact on the development of idiopathic scoliosis.

Further, in Mandl-Weber's thesis paper, his discussion is meant to show anatomical, biochemical and embryological links to the clinical symptoms of idiopathic scoliosis and concludes that "evaluation shows how general osteopathic treatment affects the idiopathic spine positively." I theory what Soler agrees with in his thesis as he concludes that osteopathy may be a preventivie factor for the development of scoliosis. Soler also states that it is recommended to continue the study.

On his website, Dr. Palmer states that the spine functions best when it is aligned properly. Scoliosis results in extra strain on the muscles, discs, joints and nerves, which can lead to muscle tightness, pain and a variety of other symptoms due to nerve interference. If left uncorrected the risk of spinal arthritis increases. Other scoliosis web sites, such as North America Spine Society's website KnowYourBack.org believe that alternative treatments to prevent curve progression or prevent further curve progression such as chiropractic medicine, physical therapy, yoga, etc. have not demonstrated any scientific value in the treatment of scoliosis. However, these and other methods can be utilized if they provide some physical benefit to the patient such as core strengthening, symptom relief, etc. These should not, however, be utilized to formally treat the curvature in hopes of improving the scoliosis.

In conclusion, few, if any, absolute contraindications exist regarding scoliosis care, just as few, if any, absolute indications for intervention exist. (Mehlman) Therefore, while there is no scientific evidence that manual osteopathic treatments can prevent curve progressions, manual osteopaths do play an important role for patients with scoliosis. The development of scoliosis cannot be prevented therefore early detection is important for timely treatment to reduce progressions. (Trobisch, Suess, and Schwab) Manual osteopath are able to identify the signs and symptoms at an early stage through postural assessments and palpation and refer the patient to a physician. As stated above, diagnosing scoliosis early provides and opportunity to treat with bracing at an early stage and reduce curve progression. Manual osteopaths can also play an important role in providing patients with core strengthening exercises and symptom relief.

Bridget Fearon
August 21, 2015
Diploma in Osteopathic Manual Practice
National Academy of Osteopathy

Resources

Adolescent Idiopathic Scoliosis (n.d.). Scoliosis Research Society (SRS) website:
http://www.srs.org/professionals/conditions_and_treatment/adolescent_idiopathic_scoliosis/treatment.htm

Dobbs, Mathhew B. December 16, 2014. *Neuromuscular Scoliosis* Retrieved from Medscape website: <http://emedicine.medscape.com/article/1266097-overview>

Dobbs, Mathhew B. December 16, 2014. *Neuromuscular Scoliosis Treatment & Management* Retrieved from Medscape website: <http://emedicine.medscape.com/article/1266097-treatment>

Eidelson, Steward G. Normal Curves of Your Spine. *Spine Universe*. August 25, 2015. Retrieved from Spine Universe website: <http://www.spineuniverse.com/anatomy/normal-curves-your-spine>.

Information and Support (n.d.). National Scoliosis Foundation's (NSF) scoliosis.org website: <http://www.scoliosis.org/info.php>

Hemivertbra. (n.d.). <http://rltwnf.tistory.com/entry/hemivertebra>

Loibner-Gruendler, Barbara, May 1, 2010. Thesis paper. Retrieved from:
http://www.osteopathic-research.com/index.php?option=com_jresearch&view=publication&task=show&id=14795&lang=en

Luftinger, Mona, 2008. Aetiology of idiopathic scoliosis. Current biomedical research and osteopathic theories. Thesis paper. Retrieved from: http://www.osteopathic-research.com/paper_pdf/LueftingerMona.pdf

Bridget Fearon
August 21, 2015
Diploma in Osteopathic Manual Practice
National Academy of Osteopathy

Manle-Weber, Ulrike, 2000. Osteopathic Treatment of Idiopathic Scoliosis with Emphasis on the Fascial System. Thesis paper. Retrieved from: http://www.osteopathic-research.com/index.php?option=com_jresearch&view=publication&task=show&id=12299&lang=en

Mehlman, Charles T., December 18, 2014. *Idiopathic Scoliosis*. Medscape website: <http://emedicine.medscape.com/article/1265794-overview>

Palmer, Dr. David. Can Chiropractic Improve Scoliosis? February 2, 2014. *Back to Health Chiropractic Clinic*. Retrieved from [durbanchiro.co.za](http://www.durbanchiro.co.za/wp-content/uploads/2014/01/Scoliosis-Durban-Chiropractor.png) website: <http://www.durbanchiro.co.za/wp-content/uploads/2014/01/Scoliosis-Durban-Chiropractor.png>.

Roamno, Michele and Negrini Stefano, Manual therapy as a conservative treatment for adolescent idiopathic scoliosis: a systematic review. *Scoliosis* 2008, 3:2 Retrieved from: <http://www.scoliosisjournal.com/content/3/1/2>

Rodts, Mary. Surgery for Scoliosis. *Spine Universe*. February 26, 2014. Retrieved from *Spine Universe* website: <http://www.spineuniverse.com/conditions/scoliosis/surgery-scoliosis>.

scoliosis. (n.d.). *Dictionary.com Unabridged*. Retrieved from *Dictionary.com* website: <http://dictionary.reference.com/browse/scoliosis>

Scoliosis <http://www.webmd.com/osteoarthritis/guide/arthritis-scoliosis>. 2002

Scoliosis. SF Custom Chiropractic website: <http://sfcustomchiro.com/scoliosis/>

Scoliosis, Adolescent Idiopathic. (n.d.). North American Spine Society's KnowYourBack.org website: <http://www.knowyourback.org/Pages/SpinalConditions/Scoliosis/Default.aspx>

Bridget Fearon
August 21, 2015
Diploma in Osteopathic Manual Practice
National Academy of Osteopathy

Shaffrey, Christopher I. *Scoliosis in Children: From Diagnosis to Treatment*. May 19, 2014.
Retrieved from Spine Universe website:
<http://www.spineuniverse.com/conditions/scoliosis/scoliosis-children>.

Soler, Meritxell Fernandez, 2011. The approach of cranial osteopathy in infantile scoliosis.
Thesis paper. Retrieved from: http://www.osteopathic-research.com/index.php?option=com_jresearch&view=publication&task=show&id=14962&lang=en

Treatment Options, July 22, 2008. iScoliosis website: <http://www.iscoliosis.com/treatment.html>

Trobisch, Per, Suess, Olaf, and Schwab, Frank, Idiopathic Scoliosis. *Continuing Medical Education* (December 2010) 107(4): 875-884. Retrieved from:
<https://www.ncbi.nlm.nih.gov/pmc/articles/PMC3011182/>

What is Congenital Scoliosis? (n.d.).
<http://www.scoliosis.org/resources/medicalupdates/congenital.php>

What is Degenerative Scoliosis? (n.d.). National Scoliosis Foundation's scoliosis.org website:
<http://www.scoliosis.org/resources/medicalupdates/degenerative.php>

What is Scoliosis? Children's Healthcare of Atlanta website: <http://www.choa.org/Childrens-Hospital-Services/Orthopaedics/Programs-Services/Scoliosis-Screening/What-is-Scoliosis>

What is Scoliosis? Retrieved from: <http://dxline.info/diseases/scoliosis-curvature-of-the-spine>